

The Breast

Surgical anatomy

The protuberant part of the human breast is generally described as overlying the 2nd to the 6th ribs, and extending from the lateral border of the sternum to the anterior axillary line. Actually, a thin layer of mammary tissue extends considerably farther from the clavicle above to the 7th or 8th ribs below, and from the midline to the edge of latissimus dorsi posteriorly.

The axillary tail of the breast is of considerable surgical importance. In some normal cases it is palpable, and in a few it can be seen premenstrually or during lactation. A well-developed axillary tail is sometimes mistaken for a mass of enlarged lymph nodes or a lipoma.

The lobule is the basic structural unit of the mammary gland. The number and size of the lobules vary enormously: they are most numerous in young women. From 10 to over 100 lobules empty via ductules into a lactiferous duct of which there are from 15 to 20.

The ligaments of Cooper are hollow conical projections of fibrous tissue filled with breast tissue, the apices of the cones being attached firmly to the superficial fascia and thereby to the skin overlying the breast. These ligaments account for the dimpling of the skin overlying a carcinoma.

The areola contains involuntary muscle arranged in concentric rings as well as radially in the subcutaneous tissue. The areolar epithelium contains numerous sweat glands and sebaceous glands, the latter of which enlarge during pregnancy and serve to lubricate the nipple during lactation (Montgomery's tubercles).

The nipple is covered by thick skin with corrugations. Near its apex lie the orifices of the lactiferous ducts. The nipple contains smooth muscle fibres arranged concentrically and longitudinally; thus is an erectile structure which points outwards.

Lymphatics of the breast drain predominantly into the axillary and internal mammary lymph nodes. The axillary nodes receive approximately 75 per cent of the drainage and are arranged in the following groups:

- ✚ lateral, along the axillary vein;
- ✚ anterior, along the lateral thoracic vessels;
- ✚ posterior, along the subscapular vessels;
- ✚ central embedded in fat in the centre of the axilla;
- ✚ interpectoral, a few nodes lying between the pectoralis major and minor muscles apical, which lie above the level of the pectoralis minor tendon in continuity with the lateral nodes and receive the efferents of all the other groups.

The apical nodes are also in continuity with the supraclavicular nodes and drain into the subclavian lymph trunk which enters the great veins directly or via the thoracic duct or jugular trunk. The sentinel node is that lymph node designated as the first axillary node draining the breast.

The internal mammary nodes are fewer in number and lie along the internal mammary vessels deep to the plane of the costal cartilages.

Investigation of the breast

Although an accurate history and clinical examination are still the most important methods of detecting breast disease there are a number of investigations which can assist in the diagnosis as follows:

Mammography

Soft tissue X-rays are taken by placing the breast in direct contact with ultrasensitive film and exposing it to low-voltage, high-amperage X-rays. The dose of radiation is approximately 0.1 Gy .

Ultrasound

Ultrasound is particularly useful in young women with dense breasts in whom mammograms are difficult to interpret, and in distinguishing cysts from solid lesions. It can also be used to localise impalpable breast lumps.

Magnetic resonance imaging

- 1) It can be useful to distinguish scar from recurrence in women who have had previous breast conservation therapy for cancer
- 2) It is the gold standard for imaging the breasts of women with implants; it may prove useful as a screening tool in high-risk women;
- 3) and it is being evaluated in the management of the axilla in both primary breast cancer and recurrent disease.

Needle biopsy/cytology

Histology can be obtained using a fine needle such as a Trucut or Corecut biopsy device under local anaesthesia. Cytology is obtained using a 21 or 23 Gauge needle and 10-ml syringe with multiple passes throughout the lump without releasing the negative pressure in the syringe. The aspirate is then smeared on to a slide which is air dried. Fine needle aspiration cytology (FNAC) is the least invasive technique of obtaining a cell diagnosis and is very accurate if both operator and cytologist are experienced.

Triple assessment

In any patient who presents with a breast lump or other symptoms suspicious of carcinoma, the diagnosis should be made by a combination of clinical assessment, radiological imaging and a tissue sample taken for either cytological or histological analysis : the so-called triple assessment.

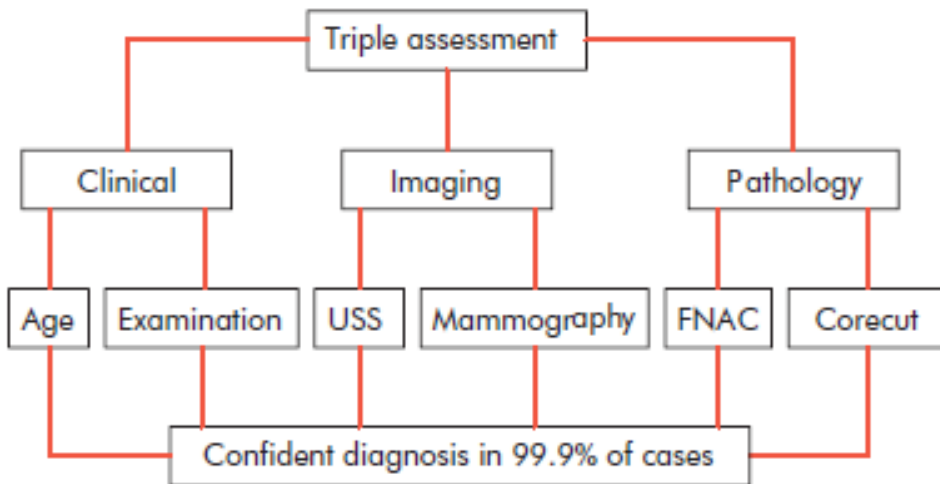


Figure 50.8 Triple assessment of breast symptoms. USS, ultrasound scan.

Diseases of the nipple

- ✚ **Absence of the nipple** is rare, and usually associated with amazia (congenital absence of the breast).
- ✚ **Supernumerary nipples** not uncommonly occur along a line extending from the anterior fold of the axilla to the fold of the groin
- ✚ **Nipple retraction: many types**
 - A. **Simple nipple inversion:** This may occur at puberty or later in life. It may cause problems with breastfeeding and infection can occur, especially during lactation, owing to retention of secretions.
Treatment
Treatment is usually unnecessary, and it may spontaneously resolve during pregnancy or lactation. Simple cosmetic surgery can produce an adequate correction but can divide the ducts. Mechanical suction devices have been used to attempt to evert the nipple with some effect.
 - B. **Recent retraction of the nipple** may be of considerable pathological significance.
 - C. **A slit-like retraction of the nipple** may be due to duct ectasia and chronic periductal mastitis
 - D. **circumferential retraction**, with or without an underlying lump, may well indicate an underlying carcinoma

✚ Cracked nipple

This may occur during lactation and be the forerunner of acute infective mastitis. If the nipple becomes cracked during lactation, it should be rested for 24—48 hours and the breast emptied with a breast pump. Feeding should be resumed as soon as possible.

✚ Papilloma of the nipple

Papilloma of the nipple has the same features of any cutaneous papilloma and should be excised with a tiny disc of skin.

✚ Retention cyst of a gland of Montgomery

These glands, situated in the areola, secrete sebum, and if they become blocked a sebaceous cyst forms.

✚ Chancre of the nipple

This very rare condition usually occurs by infection from a syphilitic buccal ulcer in the mouth of the partner, although can be seen in the wet-nurse of a syphilitic baby. The mother of such an infant is immune to reinfection from her own child.

✚ Eczema of the nipple

Eczema of the nipples is a rare condition and is bilateral, and usually associated with eczema elsewhere on the body.

✚ Paget's disease of the nipple

Paget's disease of the nipple must be distinguished from the eczema.

✚ Nipple discharge

❖ Nipple discharge can be:

1. Physiological as milk production with lactation or serous discharge during pregnancy.
2. Pathological as in duct ectasia, fibrocystic disease, duct papilloma, duct carcinoma, hyperprolactinemia or caused by taking contraceptive pills.

❖ Diagnosis can be reached through:

1. Taking history.
2. Clinical examination
3. Investigations

History and examination should provide the following in formations:

1. Nature of the discharge
2. Association with mass
3. Unilateral or bilateral
4. Single duct or multiple duct discharge
5. The use of contraceptive pills.
6. Association with pain, tenderness and fever.

Investigations include:

1. Test for occult blood in the discharge if it is not apparent.
2. Cytology of the discharge for exfoliated cancer cells.
3. Soft issue mammography

4. Duct galactography may be useful in cases of single duct discharge. The test entails cannulation of the duct and injection of contrast material (lipiodol) prior to taking the radiography. It may show a filling defect or obstruction by a papilloma or carcinoma. The test is not so practical & has been superseded by the simpler mammography.
5. Serum prolactin estimation in suspected cases of galactorrhoea.

Treatment of nipple discharge

1. First exclude CA by occult blood test & cytology & mammography.
2. Reassure the patient if there is no malignancy.
3. If the discharge is intolerable remove the duct or ducts.
4. If there is associated mass, remove it for histological examination.

Removal of the duct or ducts is achieved by:

1. For single duct discharge → microdochectomy.
2. When the duct of origin of nipple discharge is uncertain or when there is bleeding or discharge from multiple ducts then do cone excision of major lactiferous ducts.

Summary box

Discharges from the nipple (the principal causes are **Italicized** مكتوبه بأحرف مائلة)

Discharge from the surface

- ✓ ■ Paget's disease
- ✓ ■ Skin diseases (eczema, psoriasis)
- ✓ ■ Rare causes (e.g. chancre)

Discharge from a single duct

Blood-stained:

- ✓ *Intraduct papilloma*
- ✓ ■ *Intraduct carcinoma*
- ✓ ■ Duct ectasia

Serous (any colour):

- ✓ ■ *Fibrocystic disease*
- ✓ ■ *Duct ectasia*
- ✓ ■ Carcinoma

Discharge from more than one duct

Blood-stained:

- ✓ ■ *Carcinoma*
- ✓ ■ Ectasia
- ✓ ■ Fibrocystic disease

Black or green:

- ✓ ■ *Duct ectasia*

Purulent:

- ✓ ■ *Infection*

Serous:

- ✓ ■ *Fibrocystic disease*
- ✓ ■ Duct ectasia

- ✓ ■ Carcinoma

Milk:

- ✓ ■ *Lactation*
- ✓ ■ Rare causes (hypothyroidism, pituitary tumour)

Diseases of the breast

Benign breast disease

This is the most common cause of breast problems — up to 30 per cent of women will suffer from a benign breast disorder requiring treatment at some time in their lives. The most common symptoms are pain, lumpiness or a lump. The aim of treatment is to exclude cancer and, once this has been done, to treat any remaining symptoms.

Benign breast disorders can be classified in the following way:

- ✚ ANDI1 (lumpy breasts, tenderness or a smooth lump): cyclical nodularity and mastalgia, cysts, fibroadenoma;
- ✚ duct ectasia/periductal mastitis;
- ✚ pregnancy related:
 - galactocoele,
 - periperal abscess;
- ✚ congenital disorders:
 - inverted nipple,
 - supernumary breasts/nipples;
- ✚ nonbreast disorders:
 - Tietze's disease;
 - sebaceous cysts and other skin conditions.

Note:

Congenital abnormalities of the breast

Amazia

Congenital absence of the breast may occur on one or both sides. It is sometimes associated with absence of the sternal portion of the pectoralis major (Poland's syndrome). It is more common in males.

Polymazia

Accessory breasts have been recorded in the axilla (the most frequent site), groin, buttock and thigh. They have been known to function during lactation.

Mastitis of infants

Mastitis of infants is at least as common in the male as in the female. On the 3rd or 4th day of life, if the breast of an infant is pressed lightly, a drop of colourless fluid can be expressed; a few days later there is often a slight milky secretion, which disappears during the 3rd week. This is popularly known as 'witch's milk'. It is due to stimulation of the foetal breast by maternal prolactin, thus is essentially physiological.

Diffuse hypertrophy

Diffuse hypertrophy of the breasts occurs sporadically in otherwise healthy girls at puberty and, much less often, during the first pregnancy. The breasts attain enormous dimensions and may reach the knees when the patient is sitting. The condition is rarely unilateral. This tremendous overgrowth is apparently due to an alteration in the normal sensitivity of the breast to oestrogenic hormones, and some success in treating it with antioestrogens has been reported. Treatment is otherwise by reduction mammoplasty.

Injuries of the breast

Haematoma

Haematoma, particularly a resolving haematoma, gives rise to a lump which, in the absence of overlying bruising, is difficult to diagnose correctly unless it is aspirated or incised.

Traumatic fat necrosis

Traumatic fat necrosis may be acute or chronic, and usually occurs in stout, middle-aged women. Following a blow, or even indirect violence (e.g. contraction of the pectoralis major), a lump, often painless, appears. This may mimic a carcinoma, even displaying skin tethering and nipple retraction, and biopsy is required for diagnosis. A history of trauma is not diagnostic as this may merely have drawn the patient's attention to a pre-existing lump.

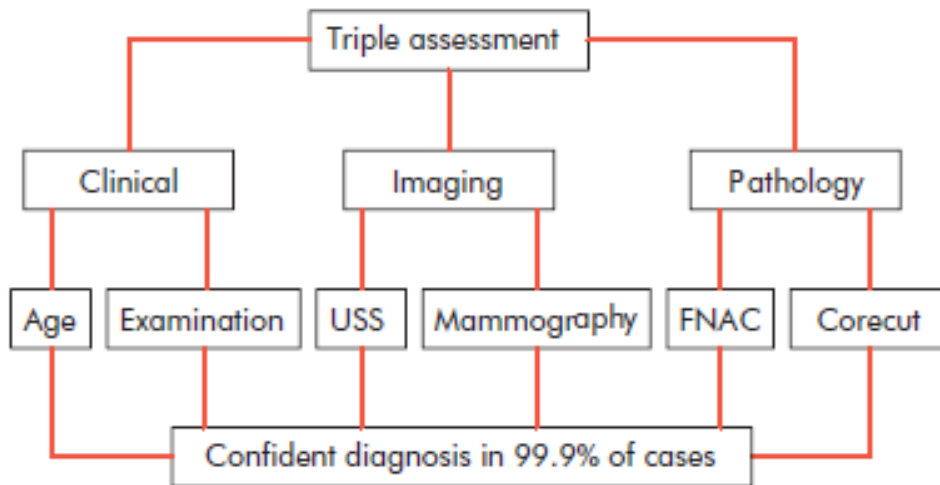


Figure 50.8 Triple assessment of breast symptoms. USS, ultrasound scan.

Acute and subacute inflammations of the breast**Bacterial mastitis**

Bacterial mastitis is the commonest variety of mastitis and nearly always commences acutely.

Causes

- 1) Of 100 consecutive cases of breast abscess, 32 occurred in women who were not lactating.
- 2) Infected haematoma
- 3) Periductal mastitis
- 4) It is frequently occurs in lactating females

Most cases are caused by *Staphylococcus aureus* and, if hospital-acquired, are likely to be penicillin resistant. The intermediary is usually the infant; after the second day of life 50 per cent of infants harbour staphylococci in the nasopharynx.

'Cleansing the baby's mouth' with a swab is also an aetiological factor. The delicate buccal mucosa is excoriated by the process; it becomes infected, and organisms in the infant's saliva are inoculated on to the mother's nipple.

Whilst ascending infection from a sore and cracked nipple may initiate the mastitis, in many cases the lactiferous ducts will first become blocked by epithelial debris leading to stasis — this theory is supported by the relatively high incidence of mastitis in women with a retracted nipple. Once within the ampulla of the duct, staphylococci cause clotting of milk and within this clot organisms multiply.

Clinical features

The affected breast, or more usually a segment of it, presents the classical signs of acute inflammation. Early on this is a generalised cellulitis, but later an abscess will form.

Treatment

During the cellulitic stage the patient should be treated with an appropriate antibiotic, e.g. flucloxacillin, and the breast rested, with feeding on the opposite side only. The infected breast should be emptied of milk using a breast pump. Support of the breast, local heat and analgesia will help to relieve pain.

If an antibiotic is used in the presence of undrained pus, an 'antibioma' may form. This is a large, sterile brawny oedematous swelling which takes many weeks to resolve.

The breast should be incised and drained if the infection does not resolve within 48 hours, or if, after being emptied of milk, there is an area of tense induration or other evidence of an underlying abscess.

The presence of pus can be confirmed with a needle aspiration, and the pus analysed for the infection and for cytology. This has the advantage of allowing diagnosis on the smear of a rare inflammatory carcinoma. In contrast to the majority of localised infections, fluctuation is a late sign and incision must not be delayed until it appears.

The usual incision is sited in a radial direction over the affected segment, although if a circumareolar incision will allow adequate access to the affected area this should be preferred because of a better cosmetic result.

Mastitis from milk engorgement

Mastitis from milk engorgement is liable to occur around weaning time, and sometimes in the early days of lactation when one of the lactiferous ducts becomes blocked with epithelial debris. In the latter instance only a sector of the breast becomes indurated and tender.

Duct ectasia/periductal mastitis

Pathology

This is a dilatation of the breast ducts associated with periductal inflammation, the pathogenesis of which is obscure and is much more common in smokers.

The first stage in the disorder is a dilatation in one or more of the larger lactiferous ducts which fill with a stagnant brown or green secretion. This may discharge. These fluids then set up an irritant reaction in surrounding tissue leading to periductal mastitis or even abscess and fistula formation. In some cases a chronic indurated mass forms beneath the areola which mimics a carcinoma. Fibrosis eventually develops which may cause slit-like nipple retraction. Anaerobic bacterial infection is found in some cases.

An association between recurrent periductal inflammation and smoking has been demonstrated which may suggest that arteriopathy is a contributing factor in its aetiology.

Clinical features

Nipple discharge (of any colour), a subareolar mass, abscess, mammary duct fistula and/or nipple retraction are the commonest symptoms.

Treatment

In the case of a mass or nipple retraction, a carcinoma must be excluded by obtaining a mammogram and negative cytology or histology. If any suspicion remains the mass should be excised.

Antibiotic therapy may be tried, the most appropriate agents being flucloxacillin and metronidazole. However, surgery is often the only option to bring about cure of this condition, and consists of excision of all of the major ducts (the Hadfield's operation).

Chronic intramammary abscess

- 1. Chronic intramammary abscess which follows inadequate drainage or injudicious antibiotic treatment** is often a very difficult condition to diagnose: when encapsulated within a thick wall of fibrous tissue, the condition cannot be distinguished from a carcinoma without the histological evidence from a biopsy.
- 2. Tuberculosis of the breast:** it is comparatively rare, is usually associated with active pulmonary tuberculosis or tuberculous cervical adenitis. Tuberculosis of the breast occurs more often in parous women and usually presents with multiple chronic abscesses and sinuses and a typical bluish attenuated appearance of the surrounding skin. The diagnosis rests on bacteriological and histological examination. Treatment is with antituberculous chemotherapy. Healing is usual although often delayed, and mastectomy should be restricted to patients with persistent residual infection.
- 3. Actinomycosis :** Actinomycosis of the breast is rarer still. The lesions present the essential characteristics of faciocervical actinomycosis.

4. **Syphilis of the breast:** A primary chancre of the nipple has been referred to (above). Secondary lesions of syphilis include diffuse syphilitic mastitis.

Mondor's disease

Mondor's disease is thrombophlebitis of the superficial veins of the breast and anterior chest wall although it has also been encountered in the arm.

The pathognomonic feature is a thrombosed subcutaneous cord, usually attached to skin. When the skin over the breast is stretched by raising the arm, a narrow, shallow subcutaneous groove alongside the cord becomes apparent. The differential diagnosis is lymphatic permeation from an occult carcinoma of the breast. The only treatment required is restricted arm movements, and in any case the condition subsides within a few months without recurrence, complications or deformity.

Muqdad fuad